

The Effect of Standard and High-Fluence Corneal Cross-Linking (CXL) on Cornea and Limbus

RICHOZ, Olivier, *et al.*

Reference

RICHOZ, Olivier, *et al.* The Effect of Standard and High-Fluence Corneal Cross-Linking (CXL) on Cornea and Limbus. *Investigative Ophthalmology & Visual Science*, 2014, vol. 55, no. 9, p. 5783

DOI : 10.1167/iov.14-14695

Available at:

<http://archive-ouverte.unige.ch/unige:78043>

Disclaimer: layout of this document may differ from the published version.



UNIVERSITÉ
DE GENÈVE

The Effect of Standard and High-Fluence Corneal Cross-Linking (CXL) on Cornea and Limbus

Olivier Richoz,¹ David Tabibian,¹ Arthur Hammer,¹ François Majo,² Michael Nicolas,² and Farhad Hafezi^{1,3}

¹Department of Ophthalmology, Geneva University Hospitals, Geneva, Switzerland

²Hôpital Ophtalmique Jules Gonin, Lausanne, Switzerland

³Keck School of Medicine, University of Southern California, Los Angeles, California, United States

Correspondence: Farhad Hafezi, Department of Ophthalmology, Geneva University Hospitals, Rue Alcide-Jentzer 22, 1211 Geneva, Switzerland; farhad@hafezi.ch.

Submitted: April 30, 2014
Accepted: July 4, 2014

Citation: Richoz O, Tabibian D, Hammer A, Majo F, Nicolas M, Hafezi F. The effect of standard and high-fluence corneal cross-linking (CXL) on cornea and limbus. *Invest Ophthalmol Vis Sci*. 2014;55:5783–5787. DOI: 10.1167/iovs.14-14695

PURPOSE. When treating peripheral ectatic disease-like pellucid marginal degeneration (PMD), corneal cross-linking with UV-A and riboflavin (CXL) must be applied eccentrically to the periphery of the lower cornea, partly irradiating the corneal limbus. Here, we investigated the effect of standard and double-standard fluence corneal cross-linking with riboflavin and UV-A (CXL) on cornea and corneal limbus in the rabbit eye in vivo.

METHODS. Epithelium-off CXL was performed in male New Zealand White rabbits with two irradiation diameters (7 mm central cornea, 13 mm cornea and limbus), using standard fluence (5.4 J/cm²) and double-standard fluence (10.8 J/cm²) settings. Controls were subjected to epithelial removal and riboflavin instillation, but were not irradiated with UV-A. Following CXL, animals were examined daily until complete closure of the epithelium, and at 7, 14, 21, and 28 days. Animals were killed and a corneoscleral button was excised and processed for light microscopy and immunohistochemistry.

RESULTS. For both irradiation diameters and fluences tested, no signs of endothelial damage or limbal vessel thrombosis were observed, and time to re-epithelialization was similar to untreated controls. Histological and immunohistochemical analysis revealed no differences in the p63 putative stem cell marker expression pattern.

CONCLUSIONS. Even when using fluence twice as high as the one used in current clinical CXL settings, circumferential UV-A irradiation of the corneal limbus does not alter the regenerative capacity of the limbal epithelial cells, and the expression pattern of the putative stem cell marker p63 remains unchanged. This suggests that eccentric CXL may be performed safely in PMD.

Keywords: corneal cross-linking, high fluence, limbal stem cells, epithelial regeneration, p63

Corneal cross-linking combines short wavelength light and a chromophore to induce specific changes in the collagen of the corneal stroma. The first change that was investigated in detail was the increase in the biomechanical stability of the cornea,^{1–3} and this specific property of CXL was used to develop therapeutic strategies for corneal ectasias, like keratoconus and postoperative ectasia.^{4,5} Another CXL-mediated effect includes changes in the tertiary structure that affect corneal packing density and swelling behavior.^{6–8} This property was used to develop treatment modalities for bullous keratopathy,^{9,10} early Fuchs' dystrophy,¹¹ and corneal edema.^{12,13} Finally, CXL increases the corneal resistance to enzymatic digestion by steric hindrance,^{14,15} a mechanism used to treat infectious and noninfectious corneal melting.^{16–20}

In certain conditions, CXL must be applied very close to the corneal limbus. Such conditions include pellucid marginal degeneration (PMD), Terrien's marginal degeneration, and also rosacea-mediated or trophic peripheral ulcers.^{20,21} Here, the UV-A irradiation must be performed in a decentered manner to cover the area of active disease, and a part of the limbal area will be exposed to short-wavelength UV-A light.²²

To investigate the potential effect of UV-A light and riboflavin on the regenerative capacity of the limbal epithelial

stem cells, we irradiated the cornea and limbus of rabbits in vivo, using the standard fluence of 5.4 J/cm² currently applied clinically, and also a fluence twice as high as the current clinical setting (10.8 J/cm²).

MATERIALS AND METHODS

Animals

All procedures concerning animals in this study adhered to the ARVO resolution for the care and use of animals in vision research. Three- to 4-month-old male New Zealand White rabbits (CrI:KBL) were used. All animals displayed a white-to-white diameter between 11 and 12 mm, and central corneal thickness (CCT), as determined by ultrasound pachymetry (Tomey SP-2000; Tomey Corporation, Nagoya, Japan), was between 600 and 700 μ m.

Cross-Linking Procedure

Animals were anesthetized using an intramuscular injection of 1.5 mL ketamine hydrochloride 10% (35 mg/kg of body weight) and 0.5 mL xylazine hydrochloride (5 mg/kg of body weight),

TABLE. Overview on the Experimental Setup Using Two Different Fluences (5.4 and 10.8 J/cm²) and Two Different Irradiation Zones

Group	No. of Animals	Fluence (Intensity × Time)	Irradiation Pattern
1	4	5.4 J/cm ² (9 mW/cm ² for 10 min)	Cornea only (7 mm)
2	4	10.8 J/cm ² (9 mW/cm ² for 20 min)	Cornea only (7 mm)
3	4	5.4 J/cm ² (9 mW/cm ² for 10 min)	Cornea and limbus (13 mm)
4	4	10.8 J/cm ² (9 mW/cm ² for 20 min)	Cornea and limbus (13 mm)

and proparacaine eye drops were applied topically. CXL was performed as described previously.²³ Briefly, corneas were de-epithelialized mechanically in a diameter of 10 to 11 mm, leaving a margin of 1 mm to the limbus. Isotonic 0.1% riboflavin solution containing 20% dextrane (MedioCross D Solution; Peschke Meditrade GmbH, Hünenberg, Switzerland) was instilled every 2 minutes for 25 minutes without the use of a speculum to avoid corneal dehydration and stromal thinning. Corneal thickness was verified immediately before irradiation by ultrasound pachymetry (Tomey SP-2000; Tomey Corporation), and all corneas used in the experiments showed no more than $\pm 10\%$ variation of central thickness when compared with thickness before riboflavin instillation.²⁴ The Table shows experimental irradiation and fluence settings: UV-A irradiation was performed in the right eye at 365 nm with a fluence of either 5.4 J/cm² (3 mW/cm² for 30 minutes) or 10.8 J/cm² (9 mW/cm² for 20 minutes) using a commercially available device (CXL-365; Schwind Eye-Tech-Solutions, Kleinostheim, Germany). The irradiation zone was either 7 mm centered on the cornea, or 13 mm, including the entire cornea and limbal area. Following CXL, ofloxacin ointment was administered three times daily until complete closure of the corneal epithelium. Animals were examined daily and the speed and extent of re-epithelialization was documented. The left eyes served as controls. Controls were treated similarly, but not irradiated with UV-A. Animals were killed 4 weeks after CXL and corneoscleral buttons were excised.

Light Microscopy and Immunohistochemistry

The corneoscleral button was fixed in formalin, paraffin-embedded. Hematoxylin and eosin staining and immunohistochemistry were performed on serial 5- μ m sections. Briefly, tissue sections were dewaxed in xylene, rehydrated through graded alcohols, and washed in water. The sections were incubated in 3% H₂O₂ in water for 10 minutes and washed in TBS (tris-buffered saline). Antigen retrieval was achieved by heat treatment (10 minutes at 97°C) using a Dako Target Retrieval Solution (Dako A/S, Glostrup, Denmark). The sections were then washed in TBS 0.1% Tween-20 and incubated in 5% BSA/TBS 0.1% Tween-20 for 2 hours at room temperature (RT) and again washed in TBS 0.1% Tween-20. Sections were incubated with the primary antibodies at RT for 2 hours. The reference and dilution factor of primary antibodies were as follows: CK 3-12 (1:30; AbCam plc, Cambridge, UK), p63 (1:500, AbCam plc) in Dako REAL Antibodies Diluent (Dako A/S). Detection was with a Vectastain ABC KIT (Vector Laboratories, Burlingame, CA, USA) using a biotinylated secondary antibody for 30 minutes at RT, washed in TBS 0.1% Tween-20, and peroxidase-streptavidin label applied for 30 minutes at RT. Sections were finally washed in TBS 0.1% Tween-20 and developed using a Vector DAB

Peroxidase Substrate kit (Vector Laboratories). Sections were washed in tap water, cleared, mounted, and examined on a light microscope (Leica DMI4000B; Leica Microsystems, Wetzlar, Germany) using Diskus 4.80 image analyzer software (Leica Microsystems).

RESULTS

Figure 1 shows the speed of re-epithelialization in corneas irradiated on 13 mm with a fluence of 5.4 J/cm² and 10.8 J/cm², and in unirradiated controls. When using the double-standard fluence of 10.8 J/cm², corneas showed a partial re-epithelialization at 24 hours (Fig. 1B) and a complete re-epithelialization at 72 hours (Fig. 1C) after CXL. Corneas that were treated using the standard fluence of 5.4 J/cm² (data not shown) and the unirradiated controls (Figs. 1E, 1F) showed a re-epithelialization speed at 24 hours and 72 hours, similar to the one observed at 10.8 J/cm² (double-standard fluence).

Light microscopic analysis of the cornea and the limbal area was performed at 4 weeks after CXL. Hematoxylin and eosin staining showed a regular morphology of the corneal stroma as well as of the corneal and limbal epithelial cells after irradiation at a fluence of 5.4 J/cm² (Figs. 2C, 2D) and 10.8 J/cm² (Figs. 2E, 2F).

Immunohistochemical analysis of the corneal-specific marker cytokeratin 3 (K3) showed similar expression in all layers of the corneal epithelium and in the suprabasal limbal epithelium for all conditions tested (Figs. 2F-K).

The p63, an important transcription factor for epithelial development and homeostasis and a putative corneal epithelial stem cell marker was analyzed after CXL with 5.4 J/cm² and 10.8 J/cm² and in unirradiated controls.²⁵ In all conditions tested, p63 showed a similar pattern with distinct expression in the basal cells and, to a lesser extent, in the superficial layers of the limbal epithelium, and absence of staining in the corneal epithelium (Figs. 2L-P).

DISCUSSION

Currently, the most common indication for CXL is classic progressive keratoconus with stromal thinning and bulging, usually occurring in the midperiphery of the cornea, 3 to 4 mm from the center. Accordingly, irradiation is performed in a centered fashion over an area of 8 to 9 mm. Besides keratoconus, CXL was successfully applied in a number of other corneal diseases like PMD, Terrien's marginal degeneration, and rosacea-mediated or trophic peripheral ulcers.^{20–22,26} All conditions have in common that they affect the periphery of the cornea rather than the center or the midperiphery. Here, irradiation must be decentered and applied in an eccentric fashion. Partial irradiation of the limbus is unavoidable, even when attempts are made to shield the limbus.

Concerning PMD, only a few cases treated by CXL have been reported in the literature so far. Steppat and colleagues (Steppat M, et al. *IOVS* 2008;49:ARVO E-Abstract 4342) reported on 13 eyes of eight patients with PMD and a clinical follow-up of 18 months. They found an arrest of PMD progression in all eyes in the absence of side effects. In particular, no clinical signs of limbal stem cell insufficiency were observed. Spadea²² described a 43-year-old patient with bilateral PMD who underwent successful CXL in his left eye. Hassan and colleagues²⁶ reported on a similar case of bilateral PMD where one eye was successfully treated with CXL. Kaya et al.²⁷ reported a case of PMD in a case series of patients with ectasia and thin corneas who was successfully treated with CXL. Finally, Hafezi et al.⁵ described a case of effective CXL for postoperative ectasia with underlying forme fruste PMD.

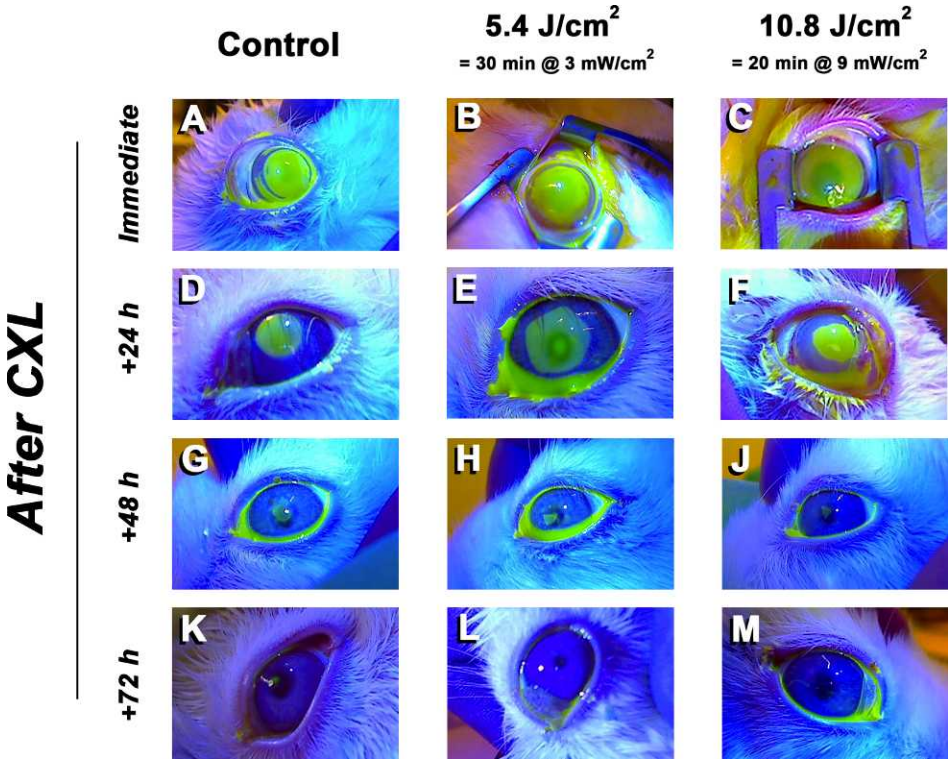


FIGURE 1. Re-epithelialization following CXL on 13 mm using standard (5.4 J/cm²) and double-standard fluence (10.8 J/cm²). The erosion was documented immediately after CXL (B, C). At 24 hours (E, F) and 48 hours (H, I) after CXL, re-epithelialization speed was similar for both fluences tested. At 72 hours after CXL, the corneal surface was fully re-epithelialized in standard and double-standard fluence corneas (L, M). The nonirradiated controls showed a similar time to re-epithelialization (A, D, G, K).

In all cases reported, the standard fluence of 5.4 J/cm² was used, at time and energy settings of 30 minutes and 3 mW/cm². Also, all cases reported that re-epithelialization was uneventful and occurred within 4 days, in the absence of side effects.

Spadea²² and Hassan et al.²⁶ reported that they had performed CXL eccentrically by decentering the irradiation zone toward the inferior periphery of the cornea. The question remains as to whether the limbal stem cells tolerate the UV-A irradiation.

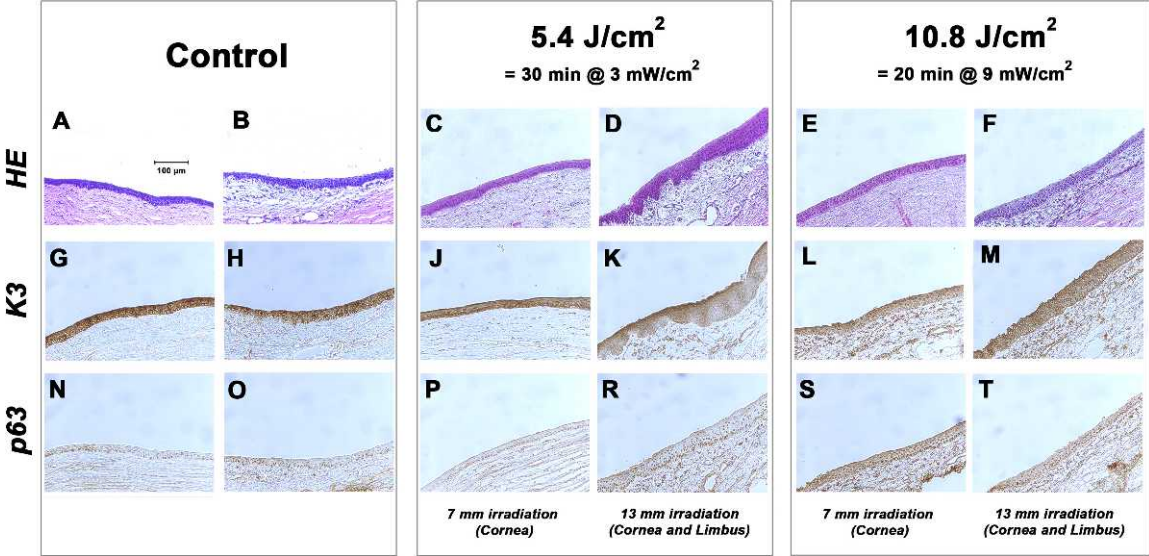


FIGURE 2. Light microscopic and immunohistochemical analysis of cornea and limbus. Corneal histology is regular at a fluence of 5.4 J/cm² when irradiating the cornea at a diameter of 7 mm (B) and cornea and limbus at a diameter of 13 mm (C), and similar to the 7-mm (D) and 13-mm (E) irradiations using double-standard fluence (10.8 J/cm²) and controls (A). Cytokeratin 3 (K3) is predominantly expressed in all layers of the corneal epithelium and in the superficial limbal epithelium and its expression pattern is similar in controls (F), at 5.4 J/cm² using 7-mm (J) and 13-mm (K) irradiation. The expression pattern of the stem cell marker p63 is also similar for all conditions tested (L–P).

Other diseases of the peripheral cornea in which CXL was applied include Terrien's marginal degeneration, and rosacea-mediated or trophic peripheral ulcers. In these cases, a decentered irradiation also was performed to cover the area of active disease.^{20,21} No limbal stem cell deficiency was reported by the authors.

The corneal epithelium shows a physiological turnover time of 7 to 14 days and also a distinct renewal capacity.^{28,29} Cotsarelis and colleagues³⁰ were the first to identify slow-cycling cells in the mouse limbus that might be responsible for this renewal capacity. A number of specific stem cell markers are known today. The cytokeratin K3 represents a corneal-specific marker that is usually expressed by all corneal epithelia and the suprabasal limbal epithelial cells and was first described by Schermer and colleagues.³¹ A marker for limbal epithelial stem cells is the transcription factor p63, which is highly expressed in the basal cell layer, and to a lesser extent in the superficial layers of the limbal epithelial cells. The p63 is not expressed in the corneal epithelium.^{32,33} In our study, we observed an expression pattern similar to untreated controls for all conditions tested (Fig. 2). Accordingly, the speed of epithelial regeneration was similar to controls for both fluences (Fig. 1 and data not shown).

When a sufficient number of stem cells is irreversibly damaged, limbal stem cell deficiency may occur, characterized by a substitution of the corneal epithelium by conjunctival epithelium and leading to corneal opacification.³⁴ Stem cells may be damaged by several mechanisms, including chemical burns, inflammatory disease, and light. Short-wavelength UV-B (290–320 nm) and UV-A (320–400 nm) light can induce mutations and apoptosis and damage various ocular structures.^{35–38} In the cornea, UV-A at 365 nm is absorbed by the corneal epithelium and can induce direct damage via oxidative stress.^{36,37,39}

All currently available CXL systems and protocols use a fluence of 5.4 J/cm² and adhere to the Bunson-Roscoe law, varying time and energy settings (30 minutes at 3 mW/cm², 10 minutes at 9 mW/cm², 5 minutes at 18 mW/cm², and 2.5 minutes at 36 mW/cm²). In our study, and in contrast to the studies reported so far, we also applied a fluence of 10.8 J/cm² (20 minutes at 9 mW/cm²). This fluence is twice as high as the one used in all current clinical settings. We deliberately used such a high fluence to test the limits of resistance of the limbal stem cells to irradiation-induced damage. Such a high dose of energy applied to the human eye would inevitably lead to decompensation of the corneal endothelium, since the threshold of endothelial damage of 0.65 J/cm² would be exceeded.⁴⁰ The rabbit cornea is distinctly thicker than the human cornea and at a thickness of 700 μ m, the surface dose at the level of the endothelium is at 0.47 J/cm² only, well below the damage threshold indicated above.

Others also have investigated the effect of CXL on the corneal limbus: in 2011, Wollensak and colleagues⁴¹ investigated the effect of sectorial CXL at a fluence of 5.4 J/cm² using 3 mW/cm² for 30 minutes on the corneal limbus in the rabbit cornea in vivo. Only the area between the 8- and 10-o'clock position was irradiated, followed by immunohistochemistry and TUNEL staining. No differences were detected between irradiated eyes and controls.

Vimalin and colleagues⁴² performed an ex vivo study on human cadaveric eyes. Following a CXL procedure using a fluence of 5.4 J/cm² (3 mW/cm² for 30 minutes), they performed cell counts of viable cells as well as RT-PCR for stem cell and corneal epithelium cell markers. They found a reduced number of viable cells and a reduction of the expression of stem cell markers like p63. Another study performed by Matalia and colleagues⁴³ measured the amount of cells undergoing apoptosis in an ex vivo model of

cultivated limbal epithelial cells: Although they showed an upregulation of proapoptotic genes like bcl-2, they failed to show a significant increase in cytotoxicity in cell culture. Finally, Moore et al.⁴⁴ recently reported on experiments on cultured human corneal epithelial cells and ex vivo human corneal tissue to detect potential DNA damage, using RT-PCR and ELISA for 8-hydroxydeoxyguanosine and cyclin-dependent kinase inhibitor genes (CDKN1A and CDKN2A). Again, and similar to the study performed by Vimalin et al.,⁴² they were able to show increases in the mRNA levels of genes mediating oxidative damage, but lacked to give direct evidence.

For an assessment of the overall risk of potential UV-mediated limbal damage, immediate, midterm, and long-term effects must be considered. Immediate and midterm effects include reduced speed of epithelial regeneration in the early postoperative phase, as well as limbal stem cell deficiency within days to weeks after CXL. The long-term effects include potential UV-A-mediated mutagenic effects. In our study, as well as in all cases reported clinically, epithelial regeneration occurred normally in the absence of signs of limbal stem cell deficiency. With a follow-up of 4 weeks corresponding to two to four times the physiological turnover time of the corneal epithelium,^{28,29} this indicates a regular immediate and midterm response of the limbal stem cells. The overall clinical follow-up of CXL currently is 15 years, and to date, no cases of limbal stem cell deficiency and/or mutagenesis have been reported. On the other hand, even longer follow-ups might be needed to exclude any long-term mutagenic effects.

In conclusion, we show that the regenerative capacity and the structural integrity of the corneal limbus are preserved after a 360-degree UV-A irradiation of the limbus using 5.4 J/cm² (standard CXL) and even 10.8 J/cm² (twice the standard fluence currently used in clinical settings), when compared with the epithelial healing rate of conventional CXL with irradiation of the cornea only.²³ Also, CXL has been in clinical use since 1999 and, to date, no case of limbal stem cell deficiency or mutagenic effects have been reported. We therefore assume that, in cases in which a sectorial CXL treatment of the corneal periphery is medically mandatory, a partial irradiation of the inferior limbus may be performed in the cornea without harm.

Acknowledgments

We thank Alain Conti for skilled technical assistance.

Supported by the Swiss National Science Foundation (OR, AH) and the Fondation Gelbert, Geneva, Switzerland (DT).

Disclosure: **O. Richoz**, P; **D. Tabibian**, None; **A. Hammer**, None; **F. Majo**, None; **M. Nicolas**, None; **F. Hafezi**, P

References

1. Spoerl E, Huhle M, Kasper M, Seiler T. Increased rigidity of the cornea caused by intrastromal cross-linking [in German]. *Ophthalmologie*. 1997;94:902–906.
2. Spoerl E, Huhle M, Seiler T. Induction of cross-links in corneal tissue. *Exp Eye Res*. 1998;66:97–103.
3. Spoerl E, Seiler T. Techniques for stiffening the cornea. *J Refract Surg*. 1999;15:711–713.
4. Wollensak G, Spoerl E, Seiler T. Riboflavin/ultraviolet-a-induced collagen crosslinking for the treatment of keratoconus. *Am J Ophthalmol*. 2003;135:620–627.
5. Hafezi F, Kanellopoulos J, Wiltfang R, Seiler T. Corneal collagen crosslinking with riboflavin and ultraviolet A to treat induced keratectasia after laser in situ keratomileusis. *J Cataract Refract Surg*. 2007;33:2035–2040.

6. Wollensak G, Aurich H, Pham DT, Wirbelauer C. Hydration behavior of porcine cornea crosslinked with riboflavin and ultraviolet A. *J Cataract Refract Surg*. 2007;33:516–521.
7. Bottos KM, Hofling-Lima AL, Barbosa MC, et al. Effect of collagen cross-linking in stromal fibril organization in edematous human corneas. *Cornea*. 2010;29:789–793.
8. Sondergaard AP, Ivarsen A, Hjortdal J. Reduction of stromal swelling pressure after UVA-riboflavin cross-linking. *Invest Ophthalmol Vis Sci*. 2013;54:1625–1634.
9. Ehlers N, Hjortdal J. Riboflavin-ultraviolet light induced cross-linking in endothelial decompensation. *Acta Ophthalmol*. 2008;86:549–551.
10. Wollensak G, Aurich H, Wirbelauer C, Pham DT. Potential use of riboflavin/UVA cross-linking in bullous keratopathy. *Ophthalmic Res*. 2009;41:114–117.
11. Hafezi F, Dejica P, Majo F. Modified corneal collagen cross-linking reduces corneal oedema and diurnal visual fluctuations in Fuchs dystrophy. *Br J Ophthalmol*. 2010;94:660–661.
12. Laborante A, Buzzonetti L, Longo C. Massive corneal edema treated with corneal cross-linking. *Clin Ter*. 2012;163:e1–e4.
13. Ehlers N, Hjortdal J, Nielsen K, Sondergaard A. Riboflavin-UVA treatment in the management of edema and nonhealing ulcers of the cornea. *J Refract Surg*. 2009;25:S803–S806.
14. Spoerl E, Wollensak G, Seiler T. Increased resistance of crosslinked cornea against enzymatic digestion. *Curr Eye Res*. 2004;29:35–40.
15. Zhang Y, Mao X, Schwend T, Littlechild S, Conrad GW. Resistance of corneal RFUVA-cross-linked collagens and small leucine-rich proteoglycans to degradation by matrix metalloproteinases. *Invest Ophthalmol Vis Sci*. 2013;54:1014–1025.
16. Iseli HP, Thiel MA, Hafezi F, Kampmeier J, Seiler T. Ultraviolet A/riboflavin corneal cross-linking for infectious keratitis associated with corneal melts. *Cornea*. 2008;27:590–594.
17. Makdoui K, Mortensen J, Crafoord S. Infectious keratitis treated with corneal crosslinking. *Cornea*. 2010;29:1353–1358.
18. Makdoui K, Mortensen J, Sorkhabi O, Malmvall BE, Crafoord S. UVA-riboflavin photochemical therapy of bacterial keratitis: a pilot study. *Graefes Arch Clin Exp Ophthalmol*. 2012;250:95–102.
19. Said DG, Elalfy MS, Gatzoufas Z, et al. Collagen cross-linking with photoactivated riboflavin (PACK-CXL) for the treatment of advanced infectious keratitis with corneal melting. *Ophthalmology*. 2014;121:1377–1382.
20. Schnitzler E, Spoerl E, Seiler T. Irradiation of cornea with ultraviolet light and riboflavin administration as a new treatment for erosive corneal processes, preliminary results in four patients [in German]. *Klin Monbl Augenheilkd*. 2000;217:190–193.
21. Hafezi F, Gatzoufas Z, Seiler TG, Seiler T. Corneal cross-linking for terrien marginal degeneration. *J Refract Surg*. 2014;30:498–500.
22. Spadea L. Corneal collagen cross-linking with riboflavin and UVA irradiation in pellucid marginal degeneration. *J Refract Surg*. 2010;26:375–377.
23. Wollensak G, Iomdina E, Dittert DD, Herbst H. Wound healing in the rabbit cornea after corneal collagen cross-linking with riboflavin and UVA. *Cornea*. 2007;26:600–605.
24. Schmidinger G, Pachala M, Prager F. Pachymetry changes during corneal crosslinking: effect of closed eyelids and hypotonic riboflavin solution. *J Cataract Refract Surg*. 2013;39:1179–1183.
25. Takacs L, Toth E, Berta A, Vereb G. Stem cells of the adult cornea: from cytometric markers to therapeutic applications. *Cytometry A*. 2009;75:54–66.
26. Hassan Z, Nemeth G, Modis L, Szalai E, Berta A. Collagen cross-linking in the treatment of pellucid marginal degeneration. *Indian J Ophthalmol*. 2014;62:367–370.
27. Kaya V, Utine CA, Yilmaz OF. Intraoperative corneal thickness measurements during corneal collagen cross-linking with hypotonic riboflavin solution in thin corneas. *Cornea*. 2012;31:486–490.
28. Haddad A. Renewal of the rabbit corneal epithelium as investigated by autoradiography after intravitreal injection of 3H-thymidine. *Cornea*. 2000;19:378–383.
29. Matsuda M, Ubels JL, Edelhauser HF. A larger corneal epithelial wound closes at a faster rate. *Invest Ophthalmol Vis Sci*. 1985;26:897–900.
30. Cotsarelis G, Cheng SZ, Dong G, Sun TT, Lavker RM. Existence of slow-cycling limbal epithelial basal cells that can be preferentially stimulated to proliferate: implications on epithelial stem cells. *Cell*. 1989;57:201–209.
31. Schermer A, Galvin S, Sun TT. Differentiation-related expression of a major 64K corneal keratin in vivo and in culture suggests limbal location of corneal epithelial stem cells. *J Cell Biol*. 1986;103:49–62.
32. Chen Z, de Paiva CS, Luo L, Kretzer FL, Pflugfelder SC, Li DQ. Characterization of putative stem cell phenotype in human limbal epithelia. *Stem Cells*. 2004;22:355–366.
33. Pellegrini G, Dellambra E, Golisano O, et al. p63 identifies keratinocyte stem cells. *Proc Natl Acad Sci U S A*. 2001;98:3156–3161.
34. Ahmad S. Concise review: limbal stem cell deficiency, dysfunction, and distress. *Stem Cells Transl Med*. 2012;1:110–115.
35. Marti A, Hafezi F, Linsel N, et al. Light-induced cell death of retinal photoreceptors in the absence of p53. *Invest Ophthalmol Vis Sci*. 1998;39:846–849.
36. Pfeifer GP, You YH, Besaratinia A. Mutations induced by ultraviolet light. *Mutat Res*. 2005;571:19–31.
37. Pitts DG, Cullen AP, Hacker PD. Ocular effects of ultraviolet radiation from 295 to 365 nm. *Invest Ophthalmol Vis Sci*. 1977;16:932–939.
38. Reme CE, Weller M, Szczesny P, et al. Light-induced apoptosis in the rat retina in vivo: morphological features, threshold and time course. In: Anderson RE, LaVail MM, Hollyfield JG, eds. *Degenerative Diseases of the Retina*. New York: Plenum Press;1995:19–25.
39. Kolozsvari L, Nogradi A, Hopp B, Bor Z. UV absorbance of the human cornea in the 240- to 400-nm range. *Invest Ophthalmol Vis Sci*. 2002;43:2165–2168.
40. Wollensak G, Mazzotta C, Kalinski T, Sel S. Limbal and conjunctival epithelium after corneal cross-linking using riboflavin and UVA. *Cornea*. 2011;30:1448–1454.
41. Wollensak G, Spoerl E, Wilsch M, Seiler T. Endothelial cell damage after riboflavin-ultraviolet-A treatment in the rabbit. *J Cataract Refract Surg*. 2003;29:1786–1790.
42. Vimalin J, Gupta N, Jambulingam M, Padmanabhan P, Madhavan HN. The effect of riboflavin-UV-A treatment on corneal limbal epithelial cells—a study on human cadaver eyes. *Cornea*. 2012;31:1052–1059.
43. Matalia H, Shetty R, Dhamodaran K, Subramani M, Arokiaraj V, Das D. Potential apoptotic effect of ultraviolet-A irradiation during cross-linking: a study on ex vivo cultivated limbal epithelial cells. *Br J Ophthalmol*. 2012;96:1339–1345.
44. Moore JE, Atkinson SD, Azar DT, et al. Protection of corneal epithelial stem cells prevents ultraviolet A damage during corneal collagen cross-linking treatment for keratoconus. *Br J Ophthalmol*. 2014;98:270–274.